

---

---

# CASE STUDY

---

---

## Specific Upper Cervical Chiropractic Management of a Patient with Parkinson's Disease: A Case Report

Tron Malachowski DC<sup>1</sup>, Shannon Goode BSc, DC<sup>2</sup>, BJ Kale DC<sup>3</sup>

---

### ABSTRACT

**Objective:** The Upper Cervical Specific Chiropractic management of a patient diagnosed with Parkinson's disease.

**Clinical Features:** A 77 year old man diagnosed with Parkinson's disease in 2003 with progressive hand tremors, festinating gait, akinesia, and incoordination.

**Intervention and Outcome:** Using Kale Upper Cervical Specific Protocol, x-ray, bilateral NeuroCaloGraph readings and neurological testing the patient was monitored and evaluated over a three and a half month period. The patient demonstrated significantly reduced trembling of his extremities and improved speed of ambulation with less exertion. Neurological findings and NeuroCaloGraph readings also improved significantly subsequent to adjusting the patient's second cervical vertebra.

**Conclusion:** Upper Cervical Specific chiropractic care of a patient diagnosed with Parkinson's disease over the course of three and a half months is presented. Marked resolution of the patient's neurological signs and symptoms associated with Parkinson's as well as a reduction in the presentation of upper cervical subluxation was obtained.

**Key Words:** *Parkinson's, Chiropractic, vertebral subluxation, upper cervical, Kale Technique, K4 neurocalograph, Knee Chest*

---

### Introduction

Parkinson's disease (PD), also known, as paralysis agitans is a progressive disorder that affects the central nervous system, characterized by tremor and impaired co-ordination. Parkinson's disease occurs when neurons in the Substantia Nigra die or become impaired, causing a decrease in dopamine production.

Dopamine is an important chemical messenger in the execution of smooth purposeful movements.<sup>1</sup> Estimates of the destruction vary from 60%-80% loss of dopamine producing cells in the brain by the time symptoms appear.<sup>1</sup>

The clinical manifestation of PD varies among individuals in the pre-motor and motor phases.<sup>2,3</sup> Although in the motor

phase PD traditionally presents with a slight trembling of an extremity, rigidity in movement, serious difficulty initiating movement, and postural instability or impaired imbalance and coordination.<sup>1</sup>

Parkinson's disease afflicts an estimated 1 million people across the United States with 50,000 newly diagnosed each year.<sup>4</sup> Historically patients go undiagnosed for years until their motor symptoms become apparent although new research suggests a prodromal phase in the progression of PD.<sup>2,3</sup>

Epidemiological data collected on Parkinson's patients demonstrate several pre-motor changes. Olfactory dysfunction, constipation, urinary disturbances, affective and cognitive changes, weight loss, and pain complaints have been found to precede the onset of motor dysfunction.<sup>3</sup> Estimates

- 
1. Private Practice of Chiropractic, Summerville, SC
  2. Private Practice of Chiropractic, Atlanta, GA
  3. Private Practice of Chiropractic, Summerville, SC

on the length of the prodromal phase vary from 2-50 years depending on the clinical feature questioned and individual variability.<sup>5</sup>

Motor symptoms are treated with medication or surgery depending on the severity of the condition. Treatment drugs include: Levodopa, a medication that is converted into dopamine in the body, which is used to facilitate muscle movement.<sup>6</sup> Dopamine agonists are prescribed to mimic the effects of dopamine. Catechol O-methyltransferase (COMT) inhibitors are drugs used along with Levodopa to prolong breakdown of Levodopa. MAO B inhibitors are used to prevent the breakdown of dopamine and Levodopa.

Anticholinergics are used to control the resting tremors associated with Parkinson's disease. Glutamate (NMDA) blocking drugs provide early short-term relief from early onset symptoms of Parkinson's.<sup>4</sup>

Surgical procedures are utilized with severely symptomatic patients. Ablation and pallidotomy are used to reduce activity of neural tissue, ablation reduces over activity by burning or freezing sections of brain and pallidotomy decreases neural activity by scar production on the globus pallidus.<sup>7</sup> Other surgical interventions include implantation of an electrical stimulation device deep within the brain to block the aberrant signals that cause tremor and PD signs and symptoms<sup>1</sup> and cerebral transplantation where dopamine rich adrenal medulla tissue is grafted on to the lateral ventricles and striatum.<sup>8</sup> These surgical treatments are based purely on managing the symptoms of Parkinson's disease as there is currently no cure.

Diagnosis of PD involves an extensive patient medical history and neurological testing. The patient may have a history of Parkinson's disease in their family, exposure to environmental toxins and physical trauma.<sup>9-11</sup> A record of any medications currently being taken is crucial. The neurological testing involves tests for coordination and movement. A diagnosis of PD is based on clinical findings, as there is no definitive test for PD.<sup>12</sup> Pathological confirmation is done post mortem with the presence of Lewy bodies in the Substantia Nigra. In Clinical practice a diagnosis of PD is considered when a patient exhibits two of the four key symptoms: resting tremors, akinesia, rigidity, and in-coordination or poor balance.<sup>7</sup>

## Case Report

### History

The patient was a 77-year-old retired shipyard worker with an occupational history of exposure to asbestos as well as trauma to the upper cervical spine. The patient was a football player, and reported being knocked unconscious in a helmet-to-helmet collision during a game in his teenage years.

He was diagnosed with Parkinson's disease in 2003 and has received medical treatment since that time including a regular regiment of Carbidopa / Levodopa taken four times daily. At the time of initial examination the patient presented with trembling in both hands, recall difficulty, a festinating gait which included a difficult time getting from a seated to standing position, difficulty with balance, and akinesia. The

patient reported the initial onset of trembling to be 2003, and has progressively degenerated since that time. The patient describes difficulty in completing activities of daily living such as brushing his teeth and bathing himself.

### Examination

The patient underwent orthopedic, neurological, thermal and radiographic examinations. Orthopedic testing revealed that the range of motion in the cervical spine was restricted, extension was noted at 30 degrees and left / right rotation was listed at 40 degrees each.

The neurological examination evaluated motor skills, comprehension, balance, recall, memory, reflexes, muscle testing, and cranial nerve testing. 29 clinical neurological exams were conducted prior to care revealing 18 positive tests including; shin rub, heel-toe, finger-nose, and Rhomberg test with eyes open and closed showing the classic presentation of motor dysfunction in Parkinson disease (Table 1).

### Instrumentation

The patient's neurophysiology was analyzed using a K4 NeuroCaloGraph,<sup>13</sup> a thermocouple device used for measuring bilateral thermographic paraspinal temperature. The K4 NeuroCaloGraph is consistent to the Kale upper cervical specific technique utilized in this study.

Asymmetric thermographic paraspinal measurements have been theorized to help determine the tone of the sympathetic nervous system as well as possible nerve injury.<sup>14</sup> Pattern analysis of paraspinal musculature was developed in the 1930's, subsequent to the Neurocalometer. The Neurocalometer invented by Dossa Evans in 1922 was originally used for break analysis and was introduced to the chiropractic profession by B.J. Palmer in 1923.<sup>15-17</sup>

Records of thermography date back to Hippocrates, who observed that disease processes were likely to be present when one side of the body was warmer than the other.<sup>16</sup> The most recent studies on thermographic technology showed excellent intra and inter examiner reliability with coefficients at .95.<sup>18</sup>

The intra and inter examiner reproducibility of thermographic technology was found to range from fair agreement .27 to excellent agreement .85 in a study done by Plaughter et al.<sup>19</sup> Owens in a pilot study measured the reproducibility of the interpreter's analysis of thermographic data on consecutive visits. The chiropractors were asked to judge the similarity of the graphs. The percent agreement between the two chiropractors on 76 graphs analyzed was 38%.<sup>20</sup> In the conclusion Owens called for an objective numerical method to contrast paraspinal thermographic scans stating it should offer an increase in the reliability and stability of establishing patterns in clinical settings and is critical to future studies. Subsequent studies have shown this to be true.<sup>18,21</sup>

Hart and Boone found a 67% to 83.6% agreement for analysis of cervical spine graphs.<sup>21</sup> Studies on the reliability and validity of the K4 NeuroCaloGraph are ongoing. Today, thermal imaging is being investigated as a tool in the diagnosis of conditions such as: headaches, lateral epicondylitis,

arthralgia, nervous system disorders, pain syndromes, vascular disorders, and soft tissue injuries.<sup>22-28</sup>

The patient's K4 thermographic evaluation revealed asymmetric temperatures side to side along the paraspinal musculature. The evaluation was performed 7 times over three visits prior to care to inquire if patient's graph readings changed, or the scan remained relatively stagnant, appearing as though there was a "pattern".<sup>29</sup> The patient's readings remained stagnant over the 7 days thus revealing the patient's pattern.

Asymmetric heat patterns have been associated with the presence of subluxation and possible pathology including Parkinson's disease.<sup>9,14,30</sup> (Figure 1) Thermographic scans were evaluated each visit, and when the scan revealed an asymmetric reading consistent with patient's pattern the patient was adjusted.

### Radiographs

Laser aligned x-rays were taken according to the Kale protocol.<sup>31</sup> These three views consisted of the following Cervical x-rays: Lateral, A-P Open Mouth, and Base Posterior (Figures 4-6). All three views allow the practitioner to view the Occipito-Atlantal-Axial area from three distinct angles using the occiput as a constant for evaluation.

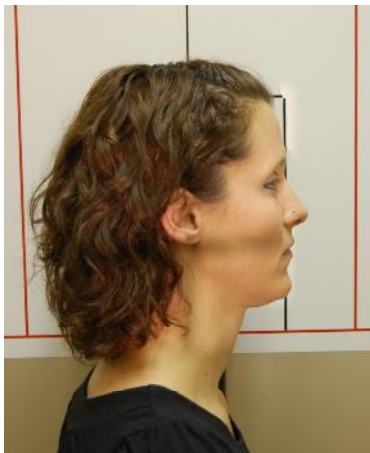

Figure 4. Lateral Cervical X-ray Patient Positioning

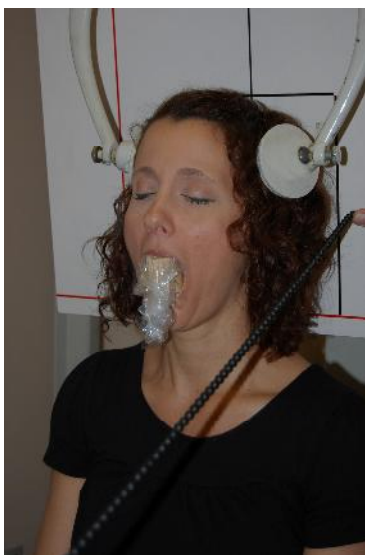

Figure 5. AP Open Mouth X-ray Patient Positioning

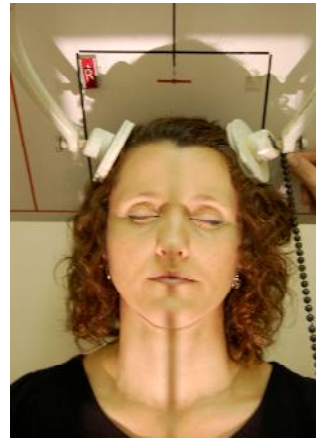

Figure 6. Base Posterior X-ray Patient Positioning

The lateral cervical x-ray showed significant degenerative disc disease, posterior joint arthrosis, and reversed cervical curve with anterior and posterior osteophytic growth. Kale upper cervical specific analysis of the lateral x-ray includes determining the atlas angle by drawing the atlas line, lateral skull line and measuring the difference. The first cervical vertebrae (C1) showed a negative 7-degree pitch where positive eight to ten degrees is average.<sup>31</sup>

The A-P Open Mouth showed uncinat hypertrophy and Kale analysis of the A-P Open Mouth x-ray showed misalignments of the C1-C2 cervical vertebrae. C1 measured 6.5 mm to the right of the arc lines used to measure atlas laterality. This measurement is taken in reference to the Foramen Magnum Line (FML). The FML represents approximately where the brain stem exits the foramen magnum entering the spinal canal.<sup>31,32</sup>

The second cervical vertebrae (C2) showed two misalignments on the APOM film, the C2 body was measured at 5 mm to the right of the FML and the C2 spinous process was recorded at 5 mm to the right of the FML. The Base Posterior (BP) analysis uses the median line and the atlas line that should intersect at 90 degrees.

The patient's BP revealed rotation of the atlas 2 degrees off perpendicular with the right transverse foramen posterior and the left transverse foramen anterior. One degree of rotation indicates significant misalignment of the first cervical vertebrae. In this case the primary vertebra to be adjusted is the second cervical.

### Intervention

The second cervical vertebra was adjusted following Kale protocol dictated by the x-ray measurements.<sup>31</sup> The patient is placed in the knee chest posture, where they kneel upon a pad or carpet and bend forward placing the head and the top of the shoulders on the upper portion of the table. The patient's thighs are perpendicular to the floor, which serves to give the lower end of the spine a fixed support.<sup>33</sup>

The spinal listing of the second cervical vertebra was noted as entire segment right, (ESR) and the patient's head was turned to the right. The doctor contacts the lamina of C2 with the pisiform of the right hand and delivers a body drop toggle torque with recoil adjustment.<sup>34</sup> Following every adjustment,

patient was taken to flat table to rest supine for 30-35 minutes.

Patient was then re-evaluated with the K4 NeuroCaloGraph to inquire if the heat distribution was symmetric as indicated by a straight line on the graph (Figure 2). When the scan revealed symmetric distribution of heat after adjustment, the patient was asked to come back for their following scheduled visit. On some visits, the pre scan revealed symmetric distribution of heat, therefore the patient was not adjusted and was asked to come back for their next visit according to their care plan (Figure 3).

### Outcome

Upper Cervical Specific Chiropractic Kale protocol was administered for 18 weeks with a neurological re-evaluation conducted after 12 weeks. Twenty-nine different neurological tests were re-conducted, showing a reduction of positive tests from 18 to 9 (Table 1). Changes of note at the time of re-examination include CN VII, dysmetria and Romberg. Initially the patient tested positive for sensorineural hearing loss on the left, with bone conduction absent and at re-exam bone conduction was reported at 7seconds.

The finger to nose test for dysmetria, initially confirmed positive bilaterally but upon re-assessment tested positive on the left and negative on the right. Romberg exam was negative upon re-exam both with eyes open and closed. The patient also reported an increase in ease when performing daily tasks such as moving from a seated to standing position, keeping his head up to look at people and ambulating.

### Discussion

Parkinson's disease is a progressive and degenerative disorder for which there is currently no cure. The medical treatment of PD is focused on symptom management through medication and surgical intervention. Currently many studies are investigating underlying causes for the disease including environmental exposure to toxins, genetics, and trauma induced upper cervical injury as well as ischemia.<sup>9-11</sup>

Elster hypothesizes that the missing link between trauma and the mechanism of neurological diseases including PD is the injury to the upper cervical spine resulting in sub-clinical ischemia of neurological tissues.<sup>9,30</sup>

Elster's premise on the affect upper cervical chiropractic adjustments have on patients with PD can be explained by a combination of two theories, central nervous system facilitation, and cerebral penumbra. Nervous system facilitation is an increase in afferent signal to the brain and spinal cord and can occur following spinal injury. This signal amplification is sent from articular mechanoreceptors within the spine.

Hyperafferent activation of the sympathetic vasomotor center occurs through CNS facilitation and can lead to sub-clinical ischemia causing neurons in the brain to hibernate. Removal of this nervous system facilitation should restore blood flow to the hibernating neurons in the substantia nigra allowing them

to resume their role in dopamine production thus reducing PD signs and symptoms.<sup>9,30</sup>

Elster's hypothesis is adequate for the patient in this study as there was trauma to his upper cervical area, vertebral subluxation was observed and while the patient underwent upper cervical care to remove the vertebral subluxation, there was marked improvement in his PD signs and symptoms. Further research into upper cervical subluxation caused by trauma and it's association with the development and progression of Parkinson's disease should be considered.

### Conclusion

This study demonstrated positive outcomes in a patient suffering from Parkinson's disease, undergoing Upper Cervical Specific chiropractic care via Kale protocol. To what extent the vertebral subluxation played a role in the neuropathophysiology of PD in this patient needs to be investigated. More research needs to be conducted on vertebral subluxation, Parkinson's disease and chiropractic care.

### References

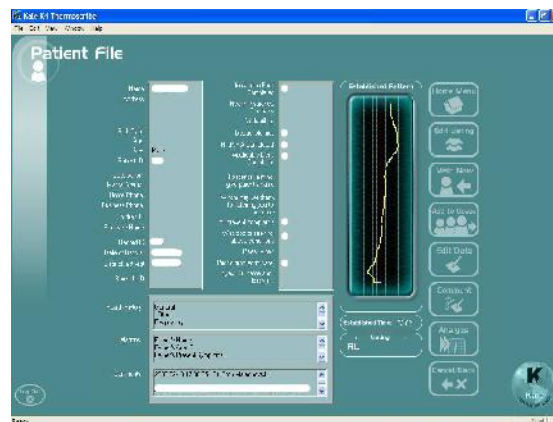1. Parkinson's Disease Information page: National Institute of Neurological Disorders and Stroke [Internet] 2011 [updated 2011 Mar 3; cited 2011 Mar 11]. Available from: [http://www.ninds.nih.gov/disorders/parkinsons\\_disease/parkinsons\\_disease.htm](http://www.ninds.nih.gov/disorders/parkinsons_disease/parkinsons_disease.htm)
2. Wolters E. Variability in the clinical expression of Parkinson's disease. *J Neurol Sci* 2008; 266:197-203.
3. Korczyn A, Gurevich T. Parkinson's Disease: Before the motor symptoms and beyond. *J Neurol Sci* 2009; 289:2-6.
4. Parkinson's Disease Treatment [Internet] 2001-2011 [cited 2011 Mar 11]. Available from: <http://www.mayoclinic.org/parkinsons-disease/treatment.html>
5. Hawkes C, Del Tredici K, Braak H. A timeline for Parkinson's disease. *Parkinsonism Relat Disord* 2009; 16:79-84.
6. Parkinson's Disease An Overview [Internet] 1995-2011 [cited 2011 Mar 11]. Available from: [http://my.clevelandclinic.org/disorders/Parkinsons\\_Disease/hic\\_Parkinsons\\_Disease\\_An\\_Overview.aspx](http://my.clevelandclinic.org/disorders/Parkinsons_Disease/hic_Parkinsons_Disease_An_Overview.aspx)
7. National Parkinson Foundation. How does your doctor make a PD diagnosis? [Internet] 2011 [cited 2011 Mar 11]. Available from: <http://www.parkinson.org/Parkinson-s-Disease/Diagnosis/How-does-your-doctor-make-a-PD-diagnosis->
8. Aminoff MJ. Treatment of Parkinson's Disease. *West J Med* 1994 Sep; 161(3):303-8.
9. Elster E. Upper Cervical Chiropractic Management of a Patient with Parkinson's Disease: A Case Report. *J Manipulative Physiol Ther* 2000; 23(8):573-577.
10. Gartner C, Battistutta D, Dunne M, Silburn P, Mellick G. Test-retest repeatability of self-reported environmental exposure in Parkinson's disease cases and healthy controls. *Parkinsonism Relat Disord* 2005; 11:287-295.
11. Elbaz A, Tranchant C. Epidemiological studies of environmental exposure in Parkinson's disease. *J Neurol Sci* 2007; 262:37-44.

12. Jankovic J. Parkinson's disease: clinical features and diagnosis. J Neurol Neurosurg Psychiatry 2008; 79:368-376.
13. Kale NeuroCaloGraph K4 [Internet] 2010 [cited 2011Mar 11]. Available from: <http://www.kale.com/k4/>
14. Uematsu S, Edwin D, Jankel WR, Kozikowski J, Trattner M. Quantification of Thermal Asymmetry. Part I. Normal Values and Reproducibility. J Neurosurg 1988; 64(4):552-555.
15. Palmer, BJ. History Repeats. Davenport IA: Palmer School of Chiropractic; 1951. p230.
16. Palmer, BJ. The Known Man. Davenport IA: Palmer School of Chiropractic; 1936. p151-163
17. Palmer, BJ. Fight to Climb. Davenport IA: Palmer School of Chiropractic;1950. p396.
18. McCoy M, Campbell I, Stone P, Fedorchuk C, Wijayawardana S, Easley K. Intra-Examiner and Inter-Examiner Reproducibility of Paraspinal Thermography. Plos one 2011; 6(2).
19. Plaugher G, Lopes M, Melch P, Cremata EE. The inter and intra-examiner reliability of a paraspinal skin temperature differential instrument. J Manipulative Physiol Ther 1991; 14(6):361-7.
20. Owens E. Thermographic pattern analysis using objective numeric methods. The Journal of Chiropractic Education 2000; 14(1):44-45.
21. Hart J, Boone W. Pattern Analysis of Paraspinal Temperatures: A descriptive Report. Journal of Vertebral Subluxation Research 199; 3(4):1-8.
22. Devereaux MD, Parr GR, Lachmann SM, Thomas Page DP, Hazleman BL. Thermographic Diagnosis in Athletes with Patellofemoral Arthralgia. J Bone Joint Surg 1986; 68:42-44.
23. Ford RG, Ford KT. Thermography in the diagnosis of headache. Semin Neurol. 1997; 17(4):343-9.
24. Bagavathiappan S, Saravanan T, Philip J, Jayakumer T, Raj B, Karunanithi R, Panicker T, Korath MP, Jagadeesan K. Infrared thermal imaging for detection of peripheral vascular disorders. J Med Phys 2009;43:43-47.
25. Kobrossi T. Clinical Use of Thermography in the Diagnosis of Soft Tissue Lesions. J Can Chirop Assoc. 1984; September; 28(3): 319-322.
26. Rho RH, Brewer RP, Lamer TJ, Wilson PR. Complex Regional Pain Syndrome. Mayo Clin Proc. 2002;77:174-180.
27. Thomas D, Siahamis G, Marion M, Boyle C. Computerized infrared thermography and isotopic bone scanning in tennis elbow. Ann Rheum Dis. 1992;51: 103-107.
28. Elster E. Upper Cervical Chiropractic Management of a Multiple Sclerosis Patient: A Case Report. J Vert Sublux Res. 2001; 4(2). 22-30.
29. Palmer BJ Chiropractic Clinical Controlled Research. Davenport IA: The BJ Palmer Chiropractic Clinic;1951. P.359-360
30. Elster E. Eighty-one Patients with Multiple Sclerosis and Parkinson's Disease Undergoing Upper Cervical Care to Correct Vertebral Subluxation: A Retrospective Analysis. J Vert Sublux Res. 2004; 1-9.
31. Kale MU Upper Cervical Specific precision x-ray, Charleston SC: the TIC institute; 2008.
32. Clark S & Ranson S The Anatomy of the Nervous System. 10<sup>th</sup> ed. : W.B. Saunders Company; 1959. p 21-22
33. Kale MU, The Knee-Chest Posture. Today's Chiropractic 1990 Jul/Aug 70-74.
34. Kale MU, Upper Cervical Specific knee-chest, Charleston SC: the TIC institute; 2008.

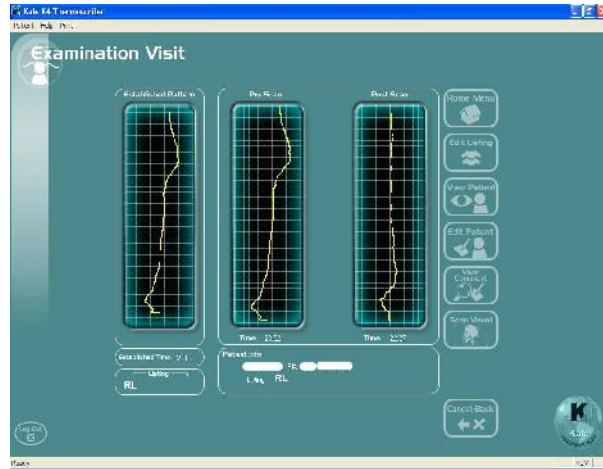
## Figures

The following photos are reproduced with permission from the Kale Chiropractic Research Clinic and the Kale World Headquarters.

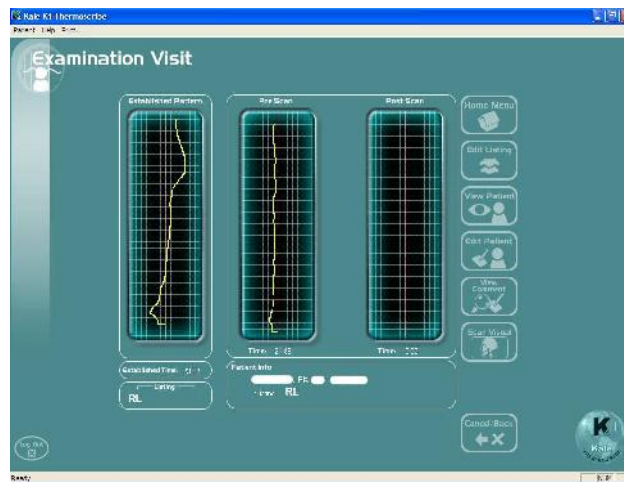
**Figure 1.** Patient pattern (on right) showing asymmetric distribution of heat.



**Figure 2.** Patient post scan (far right) showing symmetric thermographic distribution after adjustment was given.



**Figure 3.** Patient pre scan (middle) showing symmetric thermographic distribution. No adjustment was administered.



**Table 1** – Summary of Neurological testing before and after care. Showing a decrease in positive neurological tests.

	Initial	Three months later
<b>FINE MOTOR SKILLS</b>	+	+
<b>SHORT TERM MEMORY RECALL</b>	+	-
<b>COMPUTATION TIME</b>	+	-
<b>ORIENTATION</b>	+	-
<b>CN I</b>	+ bilat	+ bilat
<b>CN II</b>	+ bilat	-
<b>CN III</b>	L=+	L=+
<b>CN IV</b>	L=+	L=+
<b>CN V</b>	+ not symmetrical	-
<b>CN VI</b>	L=+	L=+
<b>CN VII</b>	-	-
<b>CN VIII</b>	L=+ sensorineural loss	L=+ SN loss *
<b>CN IX</b>	-	-
<b>CN X</b>	-	-
<b>CN XI</b>	-	-
<b>CN XII</b>	+	-
<b>BABINSKI</b>	- bilaterally	- bilat
<b>DEEP TENDON REFLEX</b>		
<b>BICEP</b>	- bilat	-bilat
<b>TRICEP</b>	-bilat	-bilat
<b>FINGER</b>	-bilat	-bilat
<b>PATELLA</b>	-bilat	- bilat
<b>DYSMETRIA</b>		
<b>FINGER TO NOSE</b>	+ bilat	L=+ R=-
<b>DYSDIADOCHOKINESIS</b>		
<b>FINGER SEQUENCE TAP</b>	+ bilat	+ bilat
<b>SHIN RUB</b>	+ bilat	+ bilat
<b>HEEL WALK</b>	-	-
<b>TOE WALK</b>	-	-
<b>RHOMBERG</b>		
<b>EYES OPEN</b>	+	-
<b>EYES CLOSED</b>	+	-
<b>HEEL TO TOE WALK</b>	+	-